

Proof of Concept Study Comparing Healing Rates of Hyaluronic Acid Hydrogel and Amniotic Drops

Introduction

Hyaluronic acid and amniotic-based hydrogels have been shown to enhance corneal healing. Considering the importance of faster reepithelialization in corneal repair and patient comfort, the aim of this study was to compare the efficacy of crosslinked hyaluronic acid based hydrogels of BioHAnce (CMHA-S) with a commercially available amniotic eye drops as well as to understand study group size to power future work.

Materials & Methods

Efforts were made to minimize the pain and discomfort of the experimental rats according to the guidelines of the Association for Research in Vision and Ophthalmology (ARVO) Statement for Use of Animals in Ophthalmic and Vision Research. In addition, the investigation was approved by "Pequeno Príncipe Hospital Complex's Ethics in Animal Use Committee, Curitiba-PR, Brazil".

In this model ten rats were anesthetized via intramuscular administration of 10% ketamine hydrochloride at a dose of 50mg/kg and 2% xylazine hydrochloride at a dose of 10 mg/kg. They also received topical application of 0.4% oxybuprocaine hydrochloride eye drops. Following anesthesia, superficial keratectomy surgery was performed on both eyes.

The size of the corneal epithelial injury was pre-established and performed using a corneal trephine 3.0mm in diameter. The area bound by the trephine was then de-epithelialized with a corneal diamond burr (AlgerBrush II), thus generating a central corneal defect, as previously described by Portela 2021.

Corneal defects were then evaluated by fluorescein stain and imaged under a blue light immediately following the surgery (time point T=0), then at 12, 24, 36, 48, and 72 hours. Each animal had one eye that served as a control and received sterile saline drops at the same frequency as experimental drops. The other eye, the treated group, received 2 drops daily of either crosslinked CMHA-S hydrogels 0.75% as prepared as previously described and provided in sterile eye drop bottles or a commercially available amniotic eye drop. Each experimental group consisted of five rats.

Following the 72 hours evaluation point, animals were euthanized and dissected. Corneas were formalin fixed, embedded in paraffin wax, and stained with H&E to evaluate cell morphology and qualitative healing.

Data Analysis & Results

The cornea was considered healed when there was no fluorescein staining on the corneal surface (Figure 1).

The following images (found on the next page) show the healing of each experimental group and their respective controls (saline eye drops) over the 72 hour evaluation time. All groups were stopped at 72 hrs even if healing did not occur.

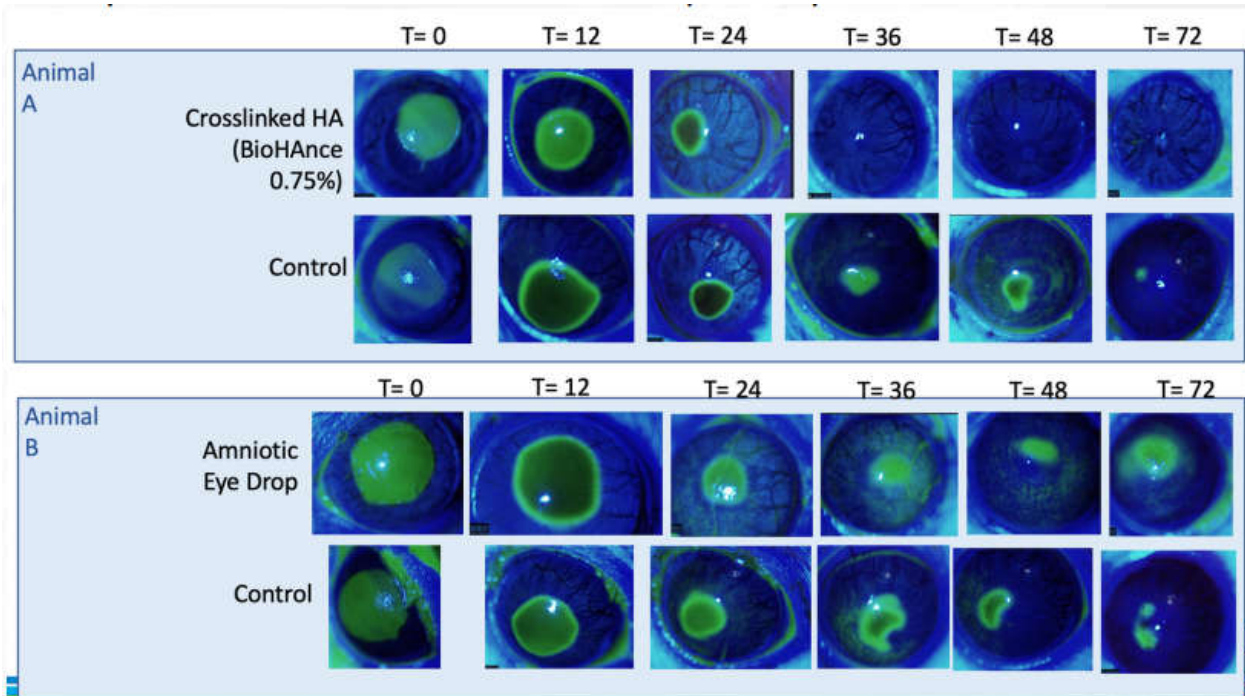


Figure 1. (shown on previous pages) Fluorescein imaging of corneal defects treated with crosslinked hyaluronic acid or amniotic eye drops compared with control (no treatment) immediately following surgery, t=0 and at time points of 12, 24, 36, 48, and 72 hours.

A paired t-test statistical analysis was performed to compare the control group with the crosslinked hyaluronic acid (BioHAnce) treated group. The treated group had a mean healing time of 48 ± 18 hours and the control group had a mean healing time of 67 ± 11 hours, although in several animals healing was not complete in the control group at the last time point. The healing time was significantly reduced ($p=0.048$) in the eyes treated with crosslinked hyaluronic acid, Figure 2.

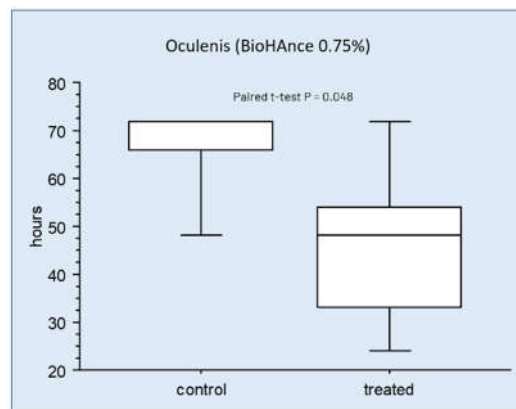


Figure 2. Box plot of time to heal comparing control (no treatment) with crosslinked hydrogel (treated). Statistical significance from a paired t-test with a p value of 0.048, n = 5. Study concluded at 72 hours, so no whisker variation is shown beyond that point.

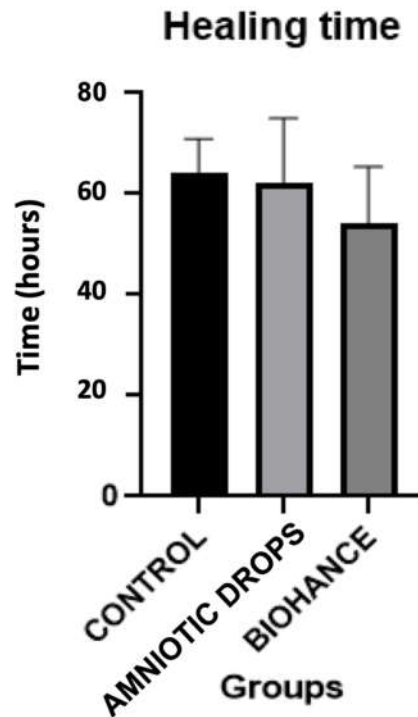


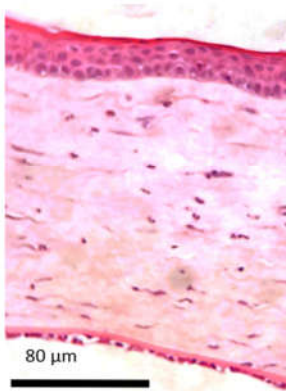
Figure 3. Time to healing comparison of control to two different treatment groups BioHAnce crosslinked HA and amniotic eye drops.

Histopathology sections were always made in central cornea, coinciding with the area in which an experimental ulceration was performed. In brief, the histopathology analysis of these slides confirmed, as expected, epithelization in the fluorescein-negative corneas and ulceration in the fluorescein-positive corneas. When compared with corneas treated with amniotic eye drops, it seemed that corneal healing went more smoothly in the rats treated with BioHAnce crosslinked HA drops. Corneal sections from rats treated with X-linked HA showed less inflammatory cells in the anterior corneal stroma and less cells with hydropic change, also called vacuolar degeneration. Normal rat corneal shows stratified squamous epithelial cells and lamellar organization of the collagen fibers of the anterior stroma. In the fully epithelialized cornea treated with BioHAnce there is mild lamellar separation of the collagen fibers due to mild stromal edema, however some of these separations may be attributed to artifacts from sectioning.

In the epithelialized corneas that were treated with amniotic eye drops there is more inflammatory cell infiltrate, specifically neutrophils in the anterior stroma, near the corneal epithelium and numerous cells with hydropic change, and vacuolar degeneration. The epithelium is not healing in the same manner in these areas. When examining a crosslinked HA treated rat in an intermediate phase during the healing process compared with amniotic eye drop treated corneas, the anterior stroma seems smoother and much more organized (closer to a lamellar organization) in the BioHAnce samples.

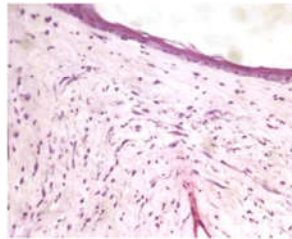
In these intermediate phase samples treated with crosslinked HA, the epithelium is not yet fully stratified. Even though there are still some inflammatory cells (which in fact are necessary for the healing process), they are not close to the epithelium. The corneal epithelium, even when starting to cover the defect like in this case, appears healthier. In the amniotic eye drop intermediate phase, the presence of numerous inflammatory cells and occasional red blood cells adjacent the corneal epithelium (anterior stroma) are observed. Additionally, numerous cells with hydropic change and vacuolar degeneration are present.

Normal Rat Cornea



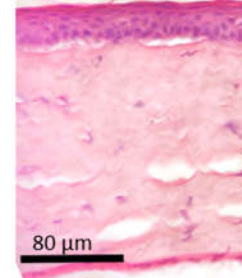
Intermediate Phase of Healing

HA hydrogel

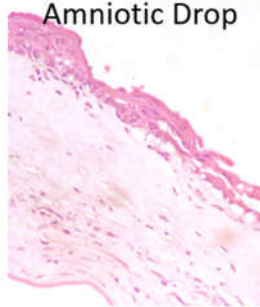


Healed at < 72 hrs

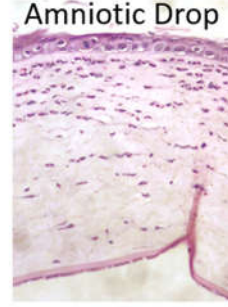
HA hydrogel



Amniotic Drop



Amniotic Drop



Saline Control (72 hrs)

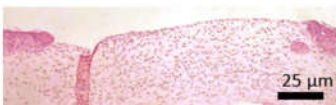

Figure 4. H&E stained sections of normal rat cornea with no injury, saline treated corneal injury, intermediate phase of healing and fully epithelialized cornea injuries treated with either crosslinked HA hydrogels, BioHance, or amniotic eye drops.

Discussion

This proof-of-concept study reinforces the greater than 50% increase in healing rates of corneal injuries treated with crosslinked hyaluronic acid hydrogels, BioHAnce, compared with saline controls. It is also worth noting that measurements for the study were formally stopped at 72 hours, in some control groups it took over 100 hours for complete reepithelization. Thus, if the experiment was not stopped at 72 hours an even greater difference in healing rates would have been seen.

BioHAnce with (CMHA-S) showed improved healing time in comparison to amniotic eye drops. This result warrants further study into the comparative efficacy of hydrogels in corneal healing time in dogs, and will be further investigated with a properly powered study. The histopathology reported here indicates that not only is healing faster with crosslinked HA it appears healthier and closer to normal uninjured morphologies.

References

1. Portela ALBM, Moreno RN, Ribeiro MHML, de Andrade FM, Alves YV, Alves M, Lira RPC. Role of nicergoline in corneal wound healing in diabetic rats. *BMC Ophthalmol.* 2021 Feb 9;21(1):77. doi: 10.1186/s12886-021-01835-4. PMID: 33563243; PMCID: PMC7871528.